HAND INJURIES IN THE WORK PLACE

Joyce Wilson, MD
JCMG Orthopedics

Hand Injuries

- 1. High pressure injection injuries
- 2. Soft tissue coverage for open wounds
- 3. Flexor tendon injuries
- 4. Mallet finger injuries

HIGH PRESSURE INJECTION INJURIES OF THE HAND (HPIIH)

HPIIH: PRINCIPLES

Biggest factor in outcome is nature of the fluid injected

1. Air and water cause little damage
   - May not need surgical intervention
2. Grease and oil
3. Paint and solvents cause most damage
   - High cytolytic effect
   - Solvents have lower viscocity and distribute faster
   - Oil based paint are highly infalmmatory compared to latex paint (water base)

HPIIH: PRINCIPLES

High pressure injection of paint is more problematic than high pressure injection of grease

Final Result	Injected Material: Grease	Injected Material: Paint
Amputation	4	5
Poor	2	0
Fair	7	0
Good	4	1

Gelberman, Posch and Jurist (JBJS(A) 1975)

HPIIH: PRINCIPLES

Injection of paint, grease or oil into the fingers leads to worse outcomes than injection into the palm

- Palm is larger than finger
  - Injection of same amount of fluid leads to compartment syndrome in the finger
  - Injection in the finger can extravasate through tendon sheath
  - Damage to tendon and pulleys leads to less funtional outcome

HPIIH: PRINCIPLES

- Do not underestimate the extent of the injury

HPIIH: PRINCIPLES

Xrays are mandatory

Antibiotics are of questionable benefit but should be given, and tetanus prophylaxis is mandatory

HPIIH: PRINCIPLES

The intervention for HPIIHs is surgical: The timing of surgical intervention should be within the first 24 hours

Ideal within 10 hours

Higher risk of amputation if delayed to 72 hours

Tempelman T, Borg D, Kon M (2004)

HPIIH: PRINCIPLES

Carpal tunnel release is of low potential morbidity
HPII of the thumb, index, middle or ring finger

Release of Guyon's canal and CTR for ulnar hand
HPII

HPIIH: PRINCIPLES

If amputation is the treatment, then patients that have undergone earlier in the course of their treatment do more favourably than those who had their amputations later on

Gelberman, Posch and Jurist (JBJS(A) 1975)

HPIIH: PRINCIPLES

Patients at their jobs less than six months, and who do not use safety mechanisms on their paint or grease guns designed specifically for the prevention of these injuries, are more likely to suffer HPIIH

Non dominant hand

Males mid 30-40s

Gelberman, Posch and Jurist (JBJS(A) 1975)

HPIIH: Principles

- They may not look like much immediately
- Amputation rate approaches 50% without adequate treatment
- Therapy starts in immediate postop period
  - MMI 6-12 months

Soft Tissue Coverage of the Finger

Soft Tissue Coverage of the Finger

- 1/3 of all traumatic injuries affects hand
- 6 million ER visits, 12 million office visits, 90 million days of restricted work, 16 million days of missed work, annual cost of 10 billion dollars

Soft Tissue Coverage of the Finger

- Primary Healing
- Skin grafting
- Local flaps

Primary healing

Primary Healing

- <1cm x 1cm wounds
- No exposed bone
- Good sensibility
- Good cosmesis
- Disadvantages
  - Prolonged healing
  - Loss of work
  - Disability while finger heals

4 weeks to healing

Skin grafts

Skin grafts

- Larger wounds- epithelium not durable and skin graft should be considered
  - Volar surface- FTSG rather than STSG
    - Contract less, more durable, less tender, better sensibility
  - Hypothenar area is preferred donor site
    - Donor graft up to 2cm
    - Close primarily

Skin Grafting Principles

- Causes of failure
  - Hematoma
  - Shear forces
  - Poor wound bed
  - Infection

Skin Grafting Principles

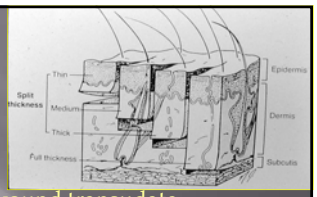

- Initially nourished by wound transudate
- Establishing vascularity is critical
- Capillary bud ingrowth in several days
  - Bed of wound >> edges
- Early grafting with splinting and compression garment- best method of preventing wound contraction

Split-Thickness Skin Graft

- Essentially unlimited supply
- Donor site heals on its own
- Can be meshed
  - More coverage
  - Poor cosmesis
- Standard thickness 0.015 inch
- Nonmeshed graft can be "pie crusted"

Full-Thickness Skin Graft

- Donor site- primary closure or STSG
- FACT: More durable and wear resistant, less contraction (palm)
- MYTH: Better sensation
- Risks- does not "take" as readily, needs a better bed, more prone to infection, limited sources

MMI 4-8 weeks

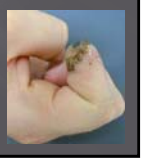

Local flaps

Moberg Advancement

- Thumb amputations distal to IP joint

Moberg Advancement

- 2 parallel incisions dorsal to NV bundle

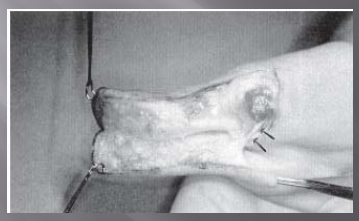

Moberg Advancement

- Volar tissue elevated from flexor sheath with N/V bundle
- Advance distally to cover tip
  - May need to flex IP joint

Fingertip Amputations

- Primary defect determines which (if any) flap can be used
- V-Y – dorsal or transverse
- Cross finger or thenar-
  - tissue loss is volar

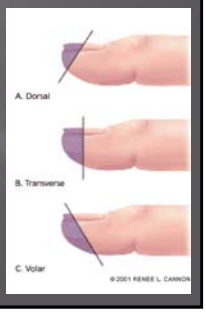

V-Y Advancement (Atasoy)

- Usually used for transverse or dorsal oblique amputations
  - First described in 1935 by Tranquili-Leali then by Atasoy in 1970
- Must be enough volar tissue for advancement
- Distal edge advanced only 1cm

V-Y Advancement (Atasoy)

- Single midline flap
- Apex of V at distal digital crease
- Free distal edge- width of the nailbed
- Problems- usually inadequate mobilization
  - Stretches vessels

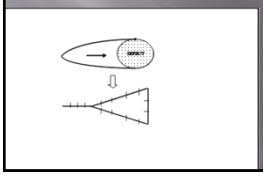

Less stitches

V-Y Advancement (Kutler)



- Used for volar/transverse amput
  exposed bone and excess lateral skin

- Double lateral V-Y flaps
- Only one NV bundle to protect in each flap
- Tend to have scar problems
- Less than ideal results

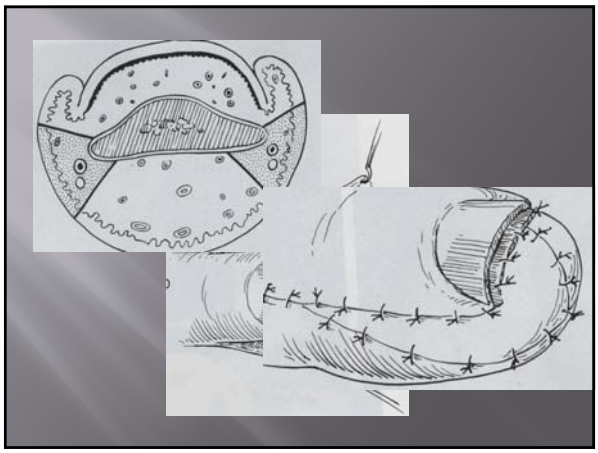

Cross Finger Flap

- Cross-finger (described by Gurdin and Pangman in 1950) and thenar flap
- Used for volar oblique, substantial pulp tissue loss, and multiple fingertip injuries
- Disadvantage is use of two stage procedure and stiffness from prolonged immobilization
- Contraindicated in pts with RA, DM, and vasospastic disorders

Cross Finger Flap

- For loss of palmar digital tissue
- From dorsal aspect, middle phalanx of adjacent finger
- Flap- midlateral to midlateral
- Skin graft donor site

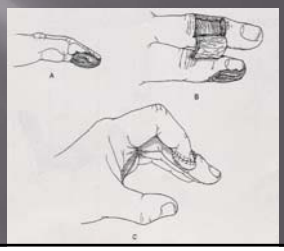

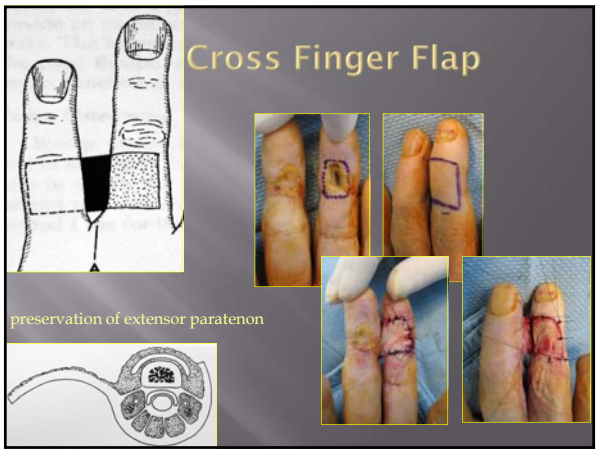

Cross Finger Flap

- Flap division done 12-14 days after initial procedure, longer delay increases stiffness
- Aggressive ROM started immediately
- Often avoided in older pts due to stiffness

Cross Finger Flap

- Studies show return of 8-10mm two-point discrimination and high satisfaction rate
- Modified technique uses transfer of dorsal sensory nerve of donor digit to injured digit for sensibility

Thenar Flap

- Controversial
- May be better for children
- Concern- tender donor scar, PIP contracture
- Proponents- Gatewood, Beasley
  - 4% PIP contracture
  - 3% hypersensitivity at donor site

Thenar Flap

- Thumb abducted
- Donor site adjacent to MP flexion crease
- Injured finger flexed to meet flap
- Flap- slightly longer, 50% wider than primary defect
- Protect radial digital nerve
- FTSG placed on donor site, if needed

Flexor tendon injuries

Flexor tendon injuries

- In the hand
  - Five zones
    - Zone 2 is the most problematic

Flexor tendon injuries

Tendon repair

- Contraindications
  - Severe multiple tissue injuries to fingers, palm
  - Gross wound contamination
  - Significant skin loss over the flexor system

Surgery Principles

- Ideal repair
  - Easy placement of sutures in the tendon
  - Secure suture knots
  - Smooth junction of tendon ends
  - Minimal gapping at the repair site
  - Minimal interference with tendon vascularity
  - Sufficient strength for early motion stress to the tendon

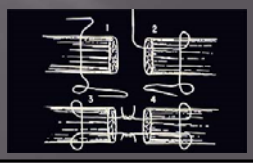

Surgery

- Core suture considerations
  - Strength of a repair is proportional to the number of suture strands crossing the repair site
  - Increasing crossing strands increases difficulty and risk of tendon damage, vascularity compromise
  - Repairs usually rupture at the suture knots
  - Locking loops configurations usually allow less gapping than grasping types
  - Larger caliber sutures increase repair strength

Surgery

- Circumferential (epitendonous) sutures
  - May provide a 20% increase in flexor tendon repair strength
  - Reduces gapping between ends



Surgery

- Strickland conclusion: Any 4-strand core suture + running lock or horizontal mattress circumferential suture should permit light composite grip during the entire healing period.

Surgery

- Sheath repair
  - Cumulative work of several investigators fails to give clear direction
  - Advantages
    - Provides a barrier to extrinsic adhesions
    - Quicker return of synovial nutrition
    - Serves as a mold for the remodeling tendon
    - Results in better sheath-tendon biomechanics
  - Disadvantages
    - Difficult
    - May restrict tendon gliding

Tendon healing

- Phases
  - Inflammatory: 48-72 hours
    - Repair strength reliant upon suture itself
  - Collagen-producing phase: 5 days to 4 weeks
    - Strength accelerates rapidly here
  - Remodeling phase: until 112 days

Tendon healing

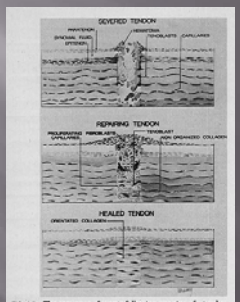

FIG. 4-5 The sequence of events following severing of a tendon. There is an initial hematoma between the tendon ends that is continuous with the general wound hematoma in injured surrounding tissue. (Rockwood CA, Green DP (eds): Fractures. Philadelphia, JB Lippincott, 1975) p 97–118

Tendon healing

- Adhesion formation and control
  - Contributing factors
    - Trauma (from injury and surgery)
      - Tendon surface crushing
      - Vincula disruption
    - Tendon ischemia
    - Tendon immobilization
    - Repair gapping
    - Excision of tendon sheath components

Tendon healing

- How is healing related to motion?
  - Passive mobilization enhances healing by stimulating tendon wound maturation and scar remodeling
  - Use a strong, gap-resistant suture technique + controlled-motion stress postoperatively
  - 3-5 mm of excursion needed at repair site to prevent adhesions

Kleinert

- Passive flexion



Active extension

Duran

- Passive positioning

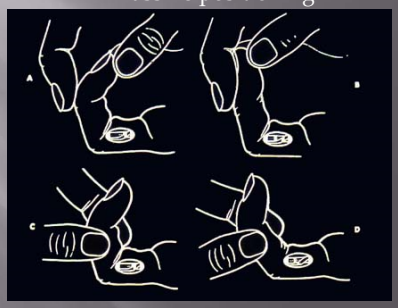

Silfverskiöld, *JHS 1993*

- Metallic markers in tendon repair
- Passive motion does not always equal tendon gliding

The Present

- The only thing clinically proven to decrease adhesion formation without adversely affecting repair strength is encouragement of motion between tendon and its sheath

Current Trend

- Increase strength of repair
- Immediate active flexion to limit adhesions

Post-Op Day 1

Start place and hold

- Test pull through
- Can't do this with passive flexion program

Full Active Range of Motion at 3 Weeks

Early Active Motion

- Indications:
  - Time from repair (48-72 hours)
  - Strong suture technique
  - Absence of conflicting injuries
  - Reliable patient (motivated)
  - Knowledgeable therapist

Early Active Motion

- 0-6 weeks
  - DBS wrist (neutral) MP's (50°-70°), IP's (neutral)
  - PROM
  - Light active muscle contraction
    - – ¼ fist, ½ fist , full fist
    - – Place-hold
- 6 weeks
  - D/C DBS
  - Gradual use
- 10-12 weeks
  - Job Simulation
  - Gradual heavier use

Is Active Motion for Everyone?

Summary

- Provide end-to-end repair
- "Atraumatic" technique

- Sufficient strength to prevent gapping and rupture to allow EAM protocols

MALLET FINGER

Mallet Finger

- Loss of continuity of extensor tendon over DIP with resultant flexion deformity of distal finger
- Most frequently involved are digits from long, ring and small finger of dominant hand
- Mostly male in young to middle ages, women with this injury tend to be older

Anatomy

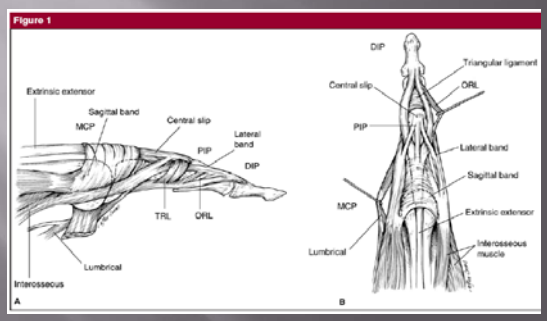

Classification

- Acute is defined as within 4 weeks
- Chronic defined as after 4 weeks
- Type IVC are associated with DIP joint volar subluxation

Table 1

Doyle's Classification of Mallet Finger Injuries[2]

Type	Description
I	Closed injury, with or without small dorsal avulsion fracture
II	Open injury (laceration)
III	Open injury (deep abrasion involving skin and tendon substance)
IV	Mallet fracture
	A Distal phalanx physeal injury (pediatric)
	B Fracture fragment involving 20% to 50% of articular surface (adult)
	C Fracture fragment >50% of articular surface (adult)

Clinical Presentation

- Have pain ,deformity and difficulty to use affected finger
- Usually have extensor lag (may present hours or days later)
- Concurrent swan neck deformity can sometimes be elicited with active finger extension

Treatment options

Three different mallet finger splints. **A**, Stack splint (Stax Finger Splint, Sammons Preston Rolyan, Bolingbrook, IL). **B**, Perforated thermoplastic splint (Aquaplast Splinting Material, Sammons Preston Rolyan). **C**, Aluminum foam splint.

- Satisfactory outcome can be defined as residual extensor lag of <20 degrees, DIP flexion arc of > 50 degrees, and no pain
- Immobilization of DIP in full extension for 6-8 weeks
- Additional two weeks of nighttime use

Surgical Treatment – Type I

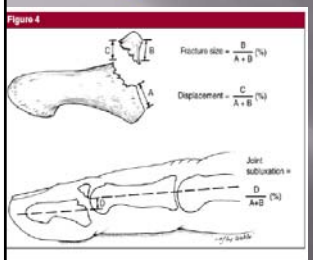

Calculations for determining fracture fragment size, fragment displacement, and distal interphalangeal joint subluxation. A and B = the length of the involved bone segments at the articular surface of the distal phalanx, C = the amount of fracture fragment displacement, D = the distance between the midaxial lines of the middle and distal phalanges. (Adapted with permission from Wehbé MA, Schneider LH: Mallet fractures. *J Bone Joint Surg Am* 1984;66:658-669.)

- Non compliant or would have difficulty performing jobs with splint
- Use K-wire across DIP to hold in extension
- Keep in for 6-8 weeks with 2 weeks additional nighttime splinting

Surgical Tx – Type II and III

- Open treatment advocated but few published reports
- Pin securing the DIP joint
- Use running suture to reapproximate tendon
- Type III may need staged reconstruction secondary to loss of skin, subQ tissue, and open bone and articular cartilage exposure

Figure 6

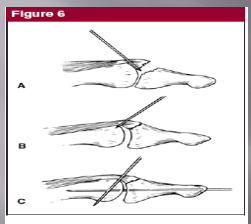

Extension block pinning technique. **A,** With the distal phalanx extended, a Kirschner wire is inserted proximal to the fractured fragment. **B,** The fracture is reduced manually by directing the exposed end of the Kirschner wire distally. **C,** The wire is drilled into the head of the middle phalanx, and a second wire is passed retrograde across the distal interphalangeal joint. (Adapted with permission from Tetik C, Gudemez E: Modification of the extension block Kirschner wire technique for mallet fractures. *Clin Orthop* 2002;404:284-290.)

- Surgical intervention advocated for mallet fractures involving greater than 1/3 of articular surface or for fractures with associated DIP subluxation
- Problems include difficulty in reducing small articular fragments, inability to accurately assess DIP joint congruency, potential to injure tenuous soft-tissue envelope.

Chronic Mallet Finger Treatment

- Greater than 4 weeks since injury
- Surgical vs Non surgical options advocated
- Splinting for 10 weeks was found to correct extensor lag in 8/10 patients in one study
- Tendon may be to lax for conservative treatment
- Examples of surgery include terminal extensor tendon shortening, tenodermosdesis, oblique retinacular ligament reconstruction, Fowler's central slip tenotomy

Chronic Mallet Finger Treatment

Figure 7

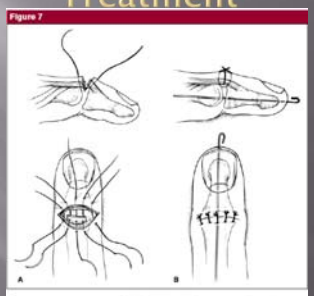

Tenodermodesis procedure in which a 3- to 4-mm elliptical wedge of skin, subcutaneous tissue, and tendon/scar is resected. **A,** The full-thickness defect is repaired with nonabsorbable sutures. **B,** Before securing the sutures, the distal interphalangeal joint is immobilized in extension with a Kirschner wire.

Complications

- Complications with nonsurgical and surgical management
- 45% complication rate with splinting, and 53% complication rate with surgery
- Most complications from splinting were transient and resolved after adjustment (skin maceration, splint pain)
- Over 76% of the surgical complications were long term (infection, nail plate deformity, joint incongruency, hardware failure, DIP joint prominence, DIP joint deformity)

Summary

- Common injury due to disruption of terminal extensor tendon mechanism overlying DIP
- Conservative management first
- Consider surgery if greater than 1/3 of articular surface or DIP subluxation
- Patient compliance is key to treatment

Thank you