Treating Thoracic Outlet Syndrome in Workers Compensation Patients

Robert Hagan, M.D.

Neuropax Clinic
PERIPHERAL NERVE SURGERY

Training

ROBERT R. HAGAN, M.D

MEDICAL SCHOOL (M.D.)
Saint Louis University
St. Louis, MO

GENERAL SURGERY
Lahey Clinic
Boston, MA

PLASTIC AND RECONSTRUCTIVE SURGERY
Lahey Clinic and Harvard Medical School
Boston, MA

HAND AND MICROSURGERY FELLOWSHIP
Harvard Medical School
Combined Plastic/ Orthopedic
Boston, MA

CRANIOFACIAL SURGERY FELLOWSHIP
Washington University
St. Louis, MO

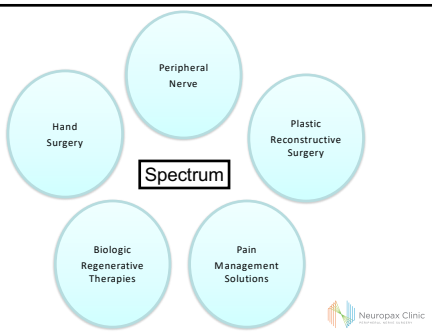

Neuropax Clinic

Most Common Work Comp Problems

- Carpal Tunnel
- Cubital Tunnel
- Thoracic Outlet syndrome
- Chronic Headaches
- Tarsal Tunnel
- Chronic Joint Pain
- Painful Limb
- Chronic Groin Pain
- Neuroma (r/o RSD)
- Hand Trauma
- Wrist Pain
- Elbow : Epicondylitis
- Lacerations
- Tendon Injury

Peripheral Nerve Injuries

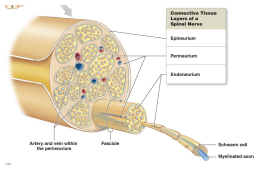

Injury
1. Cut / Laceration
2. Crushed / Contuse
3. Compressed
4. Neuroma

Peripheral Nerve Surgery

Tools
1. Decompression
2. Excise (Neurectomy)
3. Repair
4. Transfer

… whats in the tool belt

Embracing Pain….

Understanding pain will make you a better
Therapist, surgeon, care provider

Many times the final limiting factor is pain!

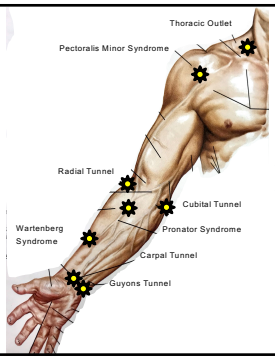

Compression Neuropathies

There are 8 compression neuropathies that affect the hand

You need to understand the whole upper extremity

If you don't know them all …… Perhaps you shouldn't treat any of them

Carpal Tunnel

- Keep it simple!
- Trial of conservative Mgt.
- Minimal Open Technique
- 17 mm incision (avg.)
- RTW 1 to 2 day

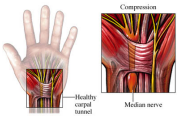

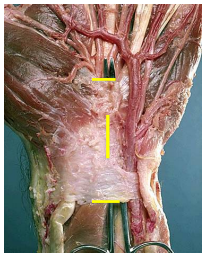

Cubital Tunnel Syndrome

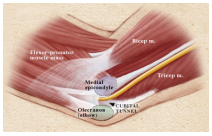

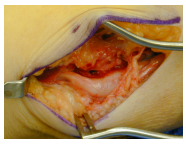

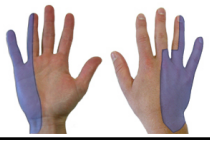

Stratified care

1. Insitu release
2. Sub cutaneous transposition
3. Sub muscular transposition

WHY TOS???.....WHO???

The trauma patient ……
The Whiplash patient ….
The Accosted patient …..
The headache patient…..
The carpal or cubital tunnel patient….
The lateral epicondilytis patient……
The shoulder pain patient…….
The rule out unknown arm pain patient…..
The neuroma patient …..

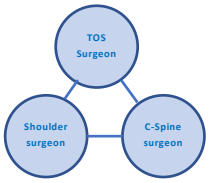

Common Interaction

Thoracic Outlet Syndrome

(Peet, Coined term in 1956)

1. Neurogenic (≥ 95%)
2. Venous (≥ 3%)
3. Arterial (< 1 %)

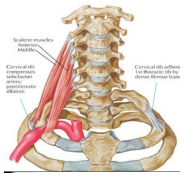

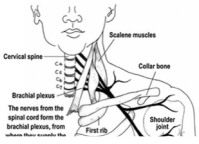

Historically treated by vascular surgeons
Despite……..95% of TOS being neurogenic

Are we doing a vascular surgery for a nerve problem?

Neurogenic.TOS … through the eyes of a peripheral nerve surgeon

Now done as an outpatient surgery and
……focuses on the composite of nerves (and artery)
emanating from the scalene triangle

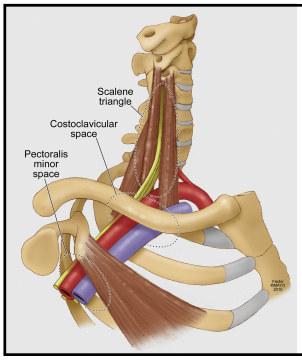

3 points of potential compression

1. Scalene Triangle

2. Costo-Clavicular Space

3. Pectoralis Minor Space

We believe that 95% have predominance of Scalene Triangle and Pectoralis Minor Syndromes ….. This supports no rib resection in the majority

Change in Nomenclature

Scalene Triangle Syndrome

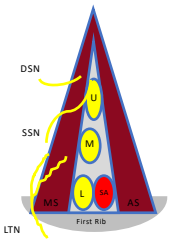

Anterior Scalene
Middle scalene
Brachial Plexus Trunks
- Upper
- Middle
- Lower

Subclavian Artery
Dorsal Scapular Nerve
Suprascapular nerve
Long Thoracic Nerve

Normal Anatomy

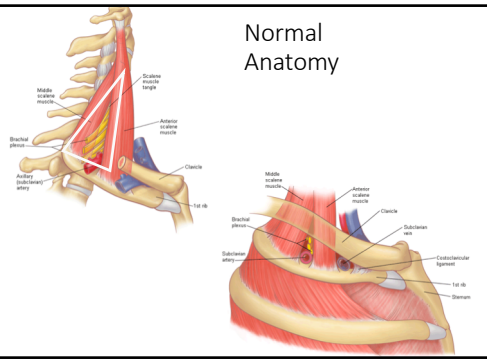

Pectoralis Minor Contribution

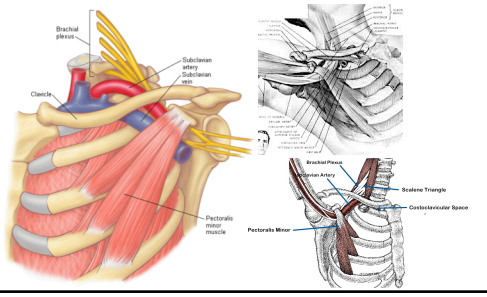

Clavi-pectoral fascia

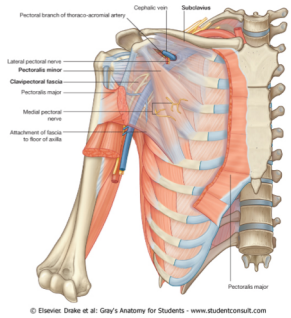

Components of injury

Scalene fibrosis and contraction
- Affects plexus
- Traction point of accessory nerves
- Primary pain from traction and elevation of first rib

Brachial plexus tethering and compression
- (the thickened rind)
- Probable peri-neural bleeding/hematoma
- Loss of nerve gliding surface
- Shrink-wrapping of surrounding fibrosis

Pectoralis Minor Syndrome
- Provides extension of the fulcrum
- Anchors entire shoulder forward and internally rotated

Subclavian Artery tethering
- Fibrosis and tethering of the artery

Scalene Fibrosis

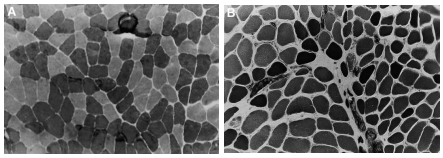

Fig. 2. Scalene muscle histology. (*A*) Control subject. (*B*) Patient with TOS. Note the increase in connective tissue around each muscle fiber in the patient with TOS. Note too the equal distribution of light and dark staining fibers (Type 1 and Type 2 fibers, respectively) in the control subject compared with the reduction in number and pleomorphism of the dark staining Type 2 fibers. *Reproduced from* Sanders RJ, Jackson CGR, Banchero J, Pearce WH. Scalene muscle abnormalities in traumatic thoracic outlet syndrome. Am J Surg 1990;159:231–6; with permission.

Anatomic Predisposition

The **most commonly described** anatomical relationship: brachial plexus (BP) lying between the anterior scalene (AS) and middle scalene (MS) muscles was **found in only 60%**

46% Scalenus minimus (bilateral in 14 cadavers).

Most common variation: penetration of the AS by the C5 and/or C6 ventral rami.

15% C5, C6 roots fuse before piercing AS (bilateral in 4)

13% C5 root alone pierce the AS (bilateral in 3).

6% C5, C6 roots independently pierce AS (bilateral in 1).

3%, the C5 root was found to be completely anterior to AS.

Anatomic Predisposition

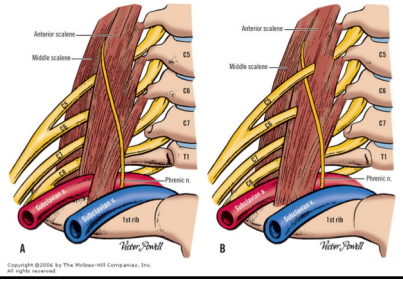

Rib Anomalies

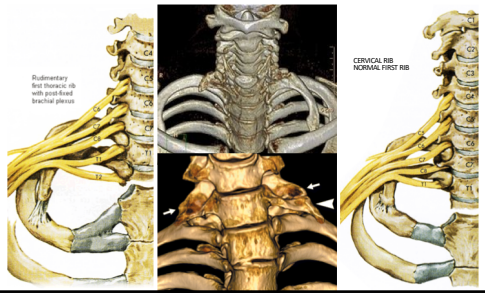

Table 1. Roos' Classification of Fibromuscular Bands and Their Relationship to the Lower Elements of the Brachial Plexus

Type	Description
1	Originates from the tip of an incomplete cervical rib and extends to the midportion of first rib; passes beneath the T1 nerve root
2	Similar to type 1, but originates from an elongated C7 transverse process and attaches to the first rib posterior to the scalene tubercle
3	Originates from the neck of the first rib medially and attaches to the inner aspect of the first rib posterior to the scalene tubercle; passes anteriorly underneath the T1 nerve root
4	Large middle scalene muscle inserting more anteriorly along the first rib; displaces the T1 nerve root anteriorly
5	Scalene minimus muscle attaching posteriorly to the subclavian artery instead of anteriorly; displaces the T1 nerve root anteriorly
6	Scalene minimus muscle that attaches to the Sibson fascia
7	Long fibromuscular band originating from the lower part of the middle scalene muscle and attaching to the costal cartilage or sternum; passes underneath T1
8	Originates from the anterior scalene muscle and attaches to the subclavius muscle and costal cartilage; main cause of subclavian vein compression
9	Sharp-edged fibromuscular band attached along the posterior inner surface of the fist rib; tightly overlies the T1 nerve root
10	Double fibrous band that forms a V over the cupola of the lung

Type 3 Example

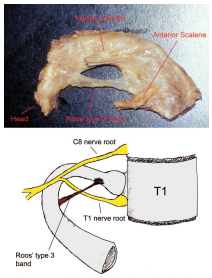

Common Symptoms

1. **Shoulder Pain**
2. **Peri-scapular Pain**
3. **Extremity Pain**
4. Facial Pain
5. Ear pain
6. Jaw pain
7. **Occipital Pain**
8. **Neck Pain**
9. **Tingling / Numbness**
10. Pain at rest
11. Pain after activities
12. Increased with overhead activities or arm traction

Multiple symptoms = look proximal

Table I. Incidence of specific symptoms in last 50 patients

Symptoms	*50 patients (%)*
Neck pain	88
Trapezius pain	92
Supraclavicular pain	76
Chest pain	72
Shoulder pain	88
Arm pain	84
Occipital headache	76
Paresthesia:	98
All 5 fingers	68
4th and 5th fingers	26
1st, 2nd fingers	14
No Paresthesia	2

Protocol

- Peripheral Nerve Consultation
- Specialty PT evaluation
- Electro-diagnostic Testing
- Radiology Studies
  - MR neurography of plexus
  - MR angiography of chest
  - C-spine x-ray
- Diagnostic Blocks (U/S guided by surgeon)
  (scalenes, plexus, pectoralis minor)

Rule out coexisting shoulder or c-spine pathology when necessary……

Examination

MULTT
EAST
Adson
Allen
Wright
SC Pressure

Neural tension or Provocative Maneuvers

Table II. Positive physical findings in 50 patients

Positive physical findings	*50 patients (%)*
Upper Limb Tension Test (ULTT)[18]	98
90° Abduction in external rotation	100
Scalene M. tenderness	94
Scalene pressure yields radiating symptoms	92
Neck rotation to opposite side	90
Head tilt to opposite side	90
Sensation to light touch	68

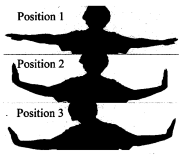

Fig. Upper Limb Tension Test (ULTT). Position 1: Arms abducted to 90° with elbows extended. Position 2: Dorsiflex wrists. Position 3: Tilt head to side, ear to shoulder. Each maneuver progressively increases stretch on the brachial plexus.

MRI/MRA and Ultrasound Modalities

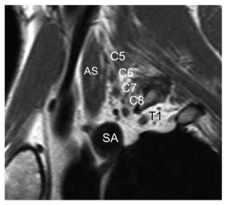

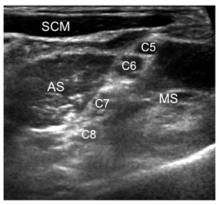

Ultrasound used for diagnostic injections and mechanical hydro-dissection

Conservative Therapy

Physical Therapy Modalities

Medications

Blocks and Steroid Injections

Botox of anterior scalene muscle

Duration and Goals with these therapies vary with each patient…….

Indications for Surgery

1. intractable pain (variable….)
2. Failed supervised physical therapy program
3. Significant neurological deficit
4. Impending vascular catastrophe
5. Persistent symptoms after more distal decompressions. (when they exist…..)



.....The Surgery

Neurolysis of Brachial Plexus
Anterior Scalenectomy
Middle Scalenectomy / Release
Decompression Subclavian artery

Neurolysis Dorsal Scapular Nerve
Neurolysis Long Thoracic Nerve
Neurolysis Suprascapular Nerve

Pectoralis Minor release

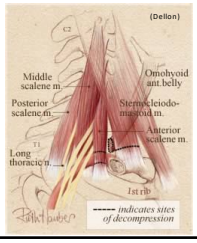

Scalene Triangle Syndrome + Pectoralis Minor Syndrome

Novel Surgical Approach for Decompression of the Scalene Triangle in Neurogenic Thoracic Outlet Syndrome

Robert R. Hagan[1][1] Joseph A. Ricci[1][2] Kyle R. Eberlin, MD[2]

[1] Neuropax Clinic, St. Louis, Missouri
[2] Division of Plastic Surgery, Massachusetts General Hospital, Harvard Medical School, Boston, Massachusetts

Address for correspondence Robert R. Hagan[1][1], Neuropax Clinic, 12855 N Outer Forty Drive Walker Medical Building North Tower, Suite 380, St. Louis, MO 63141 (e-mail: robert.r.hagan@live.com).

J Reconstr Microsurg 2018;00:1–6.

Abstract

Thoracic outlet syndrome (TOS) is a cause of upper extremity and shoulder dysfunction. TOS can present with a wide range of symptoms due to compression of the brachial plexus or its branches during their passage through the cervicothoracobrachial region or scalene triangle. There are three types of TOS: arterial, venous, and neurogenic. Neurogenic TOS (nTOS) is by far the most frequent type and represents more than 95% of all cases. Historically, surgical intervention for all types of TOS has evolved based on the treatment for a vascular etiology and has typically included a first rib resection. Despite nTOS being by far the more common type, most previous interventions have not considered treatment via peripheral nerve decompression.

We describe surgical treatment of nTOS, performed on an outpatient basis, which focuses on the surgical decompression of the structures associated with the scalene triangle in conjunction with release of the pectoralis minor insertion through limited incisions. The procedure avoids the morbidity associated with first rib resection and is successful in ameliorating nTOS symptoms. Further, we propose a nomenclature shift to scalene triangle syndrome (STS) to reflect the nerve and arterial compressions needing to be addressed.

Keywords
- neurogenic thoracic outlet syndrome
- peripheral nerve
- scalene triangle syndrome

JRMS (Journal of Reconstructive Microsurgery 2018)

Why NO RIB resection.....

Patients improve not because the rib is gone, but rather because excision of the rib requires division of anterior and middle scalene muscles.....

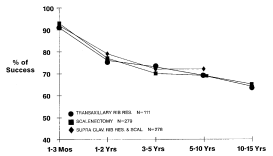

Fig. 3. Results of three primary operations for TOS. N = number of operations. (*From* Sanders RJ, Haug CE. Thoracic outlet syndrome: a common sequela of neck injuries. Philadelphia: JB Lippincott Co.; 1991. p. 182; with permission.)

Neurogenic THORACIC OUTLET SYNDROME

(nTOS) … Part of Scalene Triangle Syndrome (STS)

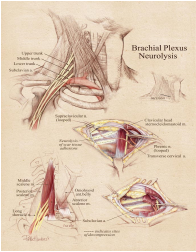

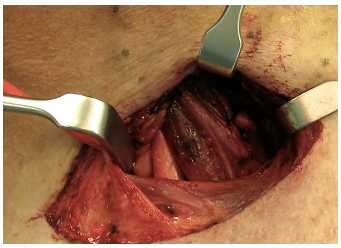

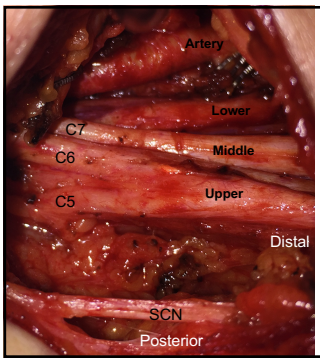

After Decompression ….

Intra-operative view of decompression

Scalene Triangle decompression

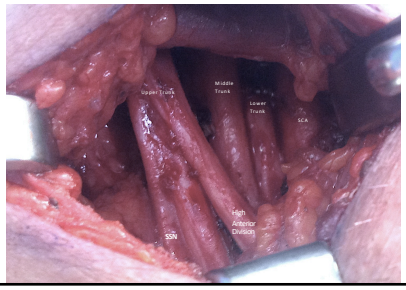

Brachial Plexus Decompression
(with Suprascapular Nerve (SSN), high takeoff)

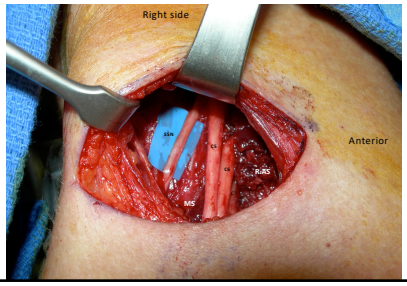

Brachial Plexus Decompression
(with **Dorsal Scapular Nerve (DSN)** decompression)

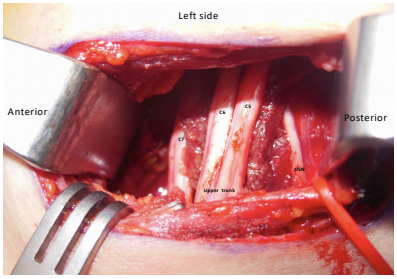

Long Thoracic Nerve (LTN) decompression from middle scalene

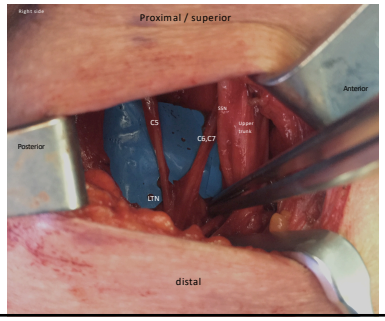

Post-Operative Course and Outcomes

Highly variable due to when they presented for treatment
(severity of symptoms, deconditioning, type of job)

Standard goal is RTW full Duty in 12 to 16 weeks

Current rate of success between 82-87%
(Historical around 70% and significant more complications)

Higher Rate of success, Higher return to work, significant less cost as outpatient

Surgery when?

- If 3 Months of guided therapy have not helped…….. Practical? …Timing of DX? .. Severity of Symptoms?
- Mechanism of Injury has significant influence.
- When symptoms have persisted after more distal nerve decompressions…..(careful diagnostics)
  - Mandates understanding of the entire extremity…. Compression neuropathies

Anatomic Predisposition

1. Cervical Rib or First Rib Anomaly
2. Actual plexus / nerve anomaly
3. Variation of Scalene Triangle
   1. Smaller size / Narrow triangle
   2. Additional muscle slips
   3. Variation in muscle morphology

Neurogenic Thoracic Outlet Syndrome (nTOS)

Brachial plexus

Peripheral Compressions

Remember…… mechanism of injury

Look proximal and distal to the Shoulder joint

Etiology

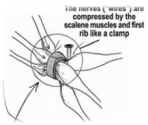

believed to be a combination of neck trauma …….plus an anatomic predisposition.

Vulnerable anatomy……..

Common Symptoms

1. **Shoulder Pain**
2. **Peri-scapular Pain**
3. **Extremity Pain**
4. Facial Pain
5. Ear pain
6. Jaw pain
7. **Occipital Pain**
8. **Neck Pain**
9. **Tingling / Numbness**
10. Pain at rest
11. Pain after activities
12. Increased with overhead activities or arm traction

Table I. Incidence of specific symptoms in last 50 patients

Symptoms	*50 patients (%)*
Neck pain	88
Trapezius pain	92
Supraclavicular pain	76
Chest pain	72
Shoulder pain	88
Arm pain	88
Occipital headache	76
Paresthesia:	98
All 5 fingers	58
4th and 5th fingers	26
1st- 3rd fingers	14
No Paresthesia	2

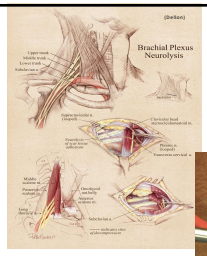

n.TOS

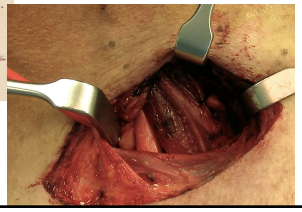

The plexus is more vertical than would imagalwaysine ……..